

Anatomy and Physiology of Headache

Biomedicine and Pharmacotherapy
1995, Vol. 49, No. 10, 435-445

N Bogduk

FROM ABSTRACT:

All headaches have a common anatomy and physiology.

All headaches are mediated by the trigeminocervical nucleus, and are initiated by noxious stimulation of the endings of the nerves that synapse on this nucleus, by irritation of the nerves themselves, or by disinhibition of the nucleus.

DR. BOGDUK ALSO NOTES:

The brainstem contains a region of grey matter called the **trigeminocervical nucleus**. This nucleus is causally continuous with the grey matter of the dorsal horn of the spinal cord.

The **trigeminocervical nucleus** is "defined by its afferent fibers." [Key]

The **trigeminocervical nucleus** receives afferents from the following sources:

- 1) Trigeminal Nerve (Cranial Nerve V)
- 2) Upper three cervical nerves
- 3) Cranial Nerve VII (Facial Nerve)
- 4) Cranial Nerve IX (Glossopharyngeal Nerve)
- 5) Cranial Nerve X (Vagus Nerve)

All of these sources of afferents terminate on common second-order neurons in the **trigeminocervical nucleus**.

Trigeminal Nerve afferents will descend to the level of C3 and perhaps as low as C4.

Afferents that enter the **trigeminocervical nucleus** at the C2 level will ascend to the C1 level and descend to the C3 level.

Afferents that enter the **trigeminocervical nucleus** at the C3 level will ascend as high as the C1 level.

The **trigeminocervical nucleus** is the sole nociceptive nucleus of the head, throat and upper neck. "All nociceptive afferents from the trigeminal, facial, glossopharyngeal and vagus nerves and C1-C3 spinal nerves ramify in this single column of grey matter."

C1 and C2 segmental neurons respond to stimulation of afferents in both the upper cervical spine and the trigeminal nerve.

Consequently, "stimulation of cervical afferents to a second-order neuron that also receives a trigeminal input may result in the source of stimulation being interpreted as arising in the cervical receptive field, the trigeminal receptive field, or both."

Pain in the forehead can arise as a result of stimulation by cervical afferents of second-order neurons in the **trigemincervical nucleus** that happen also to receive forehead afferents.

Pain in the occiput (primarily innervated by C2) may arise from trigeminal nerve stimulation.

Because the ophthalmic branch of the trigeminal nerve extends the farthest into the **trigemincervical nucleus**, cervical afferent stimulation is most likely to refer pain to the frontal-orbital region of the head.

The stimulation of any neurons that activate the **trigemincervical nucleus** can cause headache, which includes cranial nerves V, VII, IX, X, and C1-C3. "Any structure innervated by these nerves is capable of causing headache."

Structures innervated by ophthalmic branch (V1) cranial V (trigeminal):

Skin of forehead

Orbit

Eye

Frontal sinus

Dura mater of the anterior cranial fossa

Anterior and posterior ends of the falx cerebri

Superior sagittal sinus

Proximal ends of the anterior and middle cerebral arteries

Superior surface of the tentorium cerebelli

Cavernous sinus

Venous sinuses

Temporal artery

Structures innervated by maxillary branch (V2) cranial V (trigeminal):

Nose

Paranasal sinuses

Upper teeth

Upper jaw

Dura mater of the middle cranial fossa

Structures innervated by mandibular branch (V3) cranial V (trigeminal):

Dura mater of the middle cranial fossa

Lower teeth

Lower jaw
 Temporomandibular joint
 External auditory meatus (ear)
 Anterior aspect of the tympanic membrane

Structures innervated by cranial VII (facial):

Posterior aspect of the tympanic membrane

Structures innervated by cranial IX (glossopharyngeal):

Posterior aspect of the tympanic membrane
 Middle ear cavity
 Pharynx
 Larynx

Structures innervated by cranial X (vagus):

Posterior aspect of the tympanic membrane
 Pharynx
 Larynx

Structures innervated by C1-C3:

Dura mater of the posterior cranial fossa
 Inferior surface of the tentorium cerebelli
 Anterior and posterior upper cervical and cervical-occiput muscles
 OCCIPUT-C1, C1-C2, and C2-C3 joints
 C2-C3 intervertebral disc
 Skin of the occiput
 Vertebral arteries
 Carotid arteries
 Alar ligaments
 Transverse ligaments
 Trapezius muscle
 Sternocleidomastoid muscle

“The C1 and C2 spinal nerves are distinctive in that they do not emerge through intervertebral foramina.”

The C1 spinal nerve passes across the posterior arch of the atlas behind its superior articular process, descending in front of the C1 transverse process to descend as a part of the cervical plexus.

C1 spinal nerve does not supply the skin, but does supply sensory innervation to the suboccipital muscles. The sensory root of C1 can be found with the motor roots of the spinal accessory (cranial nerve XI) nerve.

The C2 spinal nerve crosses the posterior aspect of the C1-C2 facet joint; its dorsal root ganglion is opposite the midpoint of the C1-C2 facet joint.

The anterior primary rami of C1-C2-C3-C4 join and form the cervical plexus to innervate the prevertebral muscles: longus capitis, longus cervicis, rectus capitis anterior, rectus capitis lateralis, sternocleidomastoid and trapezius.

The anterior primary rami of C1-C2-C3 form the recurrent meningeal branches of the sinuvertebral nerves. These nerves innervate the anterior surface of the upper cervical dura mater, and then pass through the foramen magnum to innervate the dura mater between the pituitary gland to the anterior occiput (the clivus). They also innervate the medial portion of the C1-C2 joint capsule, the transverse and alar ligaments.

In the posterior cranial fossa, C1-C3 sinuvertebral nerves add components to cranial nerve X (vagus) and XII (hypoglossal). **[WOW!]**

The anterior primary rami from C1-C3 join the vertebral nerve, the plexus of nerves that travels with the vertebral artery, and supplies sensory branches to the fourth part of the vertebral artery.

The posterior primary rami of C1 innervate the 4 suboccipital muscles: inferior oblique, superior oblique, rectus capitis posterior major, rectus capitis posterior minor.

The motor component of the C2 posterior primary rami innervates the longissimus capitis and splenius.

The sensory component of the C2 posterior primary rami becomes the greater occipital nerve. It winds under the inferior oblique muscle, ascends and pierces the shared aponeurosis of the trapezius and sternocleidomastoid muscle to supply the posterior scalp.

The motor components of the C3 posterior primary rami also innervate the longissimus capitis and splenius muscles as well as the C2-C3 multifidus muscle.

The sensory component of the C3 posterior primary rami runs across the posterior aspect of the C2-C3 facet joint (which it innervates) and ascends as the third occipital nerve to supply the suboccipital region.

There are three mechanisms for pain generation:

1) Nociception

This type of pain is caused by stimulation of the peripheral nociceptive receptors. The stimulation is mechanical or chemical.

Mechanical stimulation "involves distortion of a network of collagen" like ligament or dura mater. **[Important]**

Chemical stimulation "requires the liberation of an algogenic chemical" like inflammation or potassium ions liberated from injured cells.

2) Neurogenic

This type of pain is caused by stimulation of the peripheral axons or cell body. The stimulation "requires ectopic generation of action potentials" for example, at the nerve root.

3) Central

This type of pain is caused by activation of second or third order neurons within the central nervous system.

This type of pain involves no tissue damage. It is classically the result of dysfunction of the descending pain inhibitory pathways. **[Important]**

Stretch on the dura mater can initiate mechanical pain. **[Important]**

The posterior cranial fossa and its contents are innervated by cervical nerves.

"Vertebral artery disease, such as an aneurysm becomes an important differential diagnosis of what otherwise might seem to be neck pain with referred pain to the head."

Arthritis of the upper cervical synovial joints (including C2-C3) can cause neck pain and headache.

Injury and damage to the alar ligaments can cause upper cervical pain and headache. The diagnosis is made with upper cervical rotational CT scanning, showing significant greater unilateral rotation.

Posterior cervical muscle tears are not a cause of chronic headache.

Trigeminal neuralgia is an example of neurogenic headache. The trigeminal sensory nerve is irritated by multiple sclerosis plaques or by irritation from an adjacent vessel or tissue.

C2 neuralgia is a neurogenic headache that can be caused by "scar tissue following trauma to the lateral atlanto-axial joint." **[Important]**
[Fibrosis of the C1-C2 facet joint affecting the adjacent C2 root]

KEY POINTS FROM DAN MURPHY

- 1) All headaches have a common anatomy and physiology.
- 2) All headaches are mediated by the **trigemincervical nucleus**, and are initiated by noxious stimulation of the endings of the nerves that synapse on this nucleus, by irritation of the nerves themselves, or by disinhibition of the nucleus.
- 3) The brainstem and upper cervical spinal cord contains a region of grey matter called the **trigemincervical nucleus**.

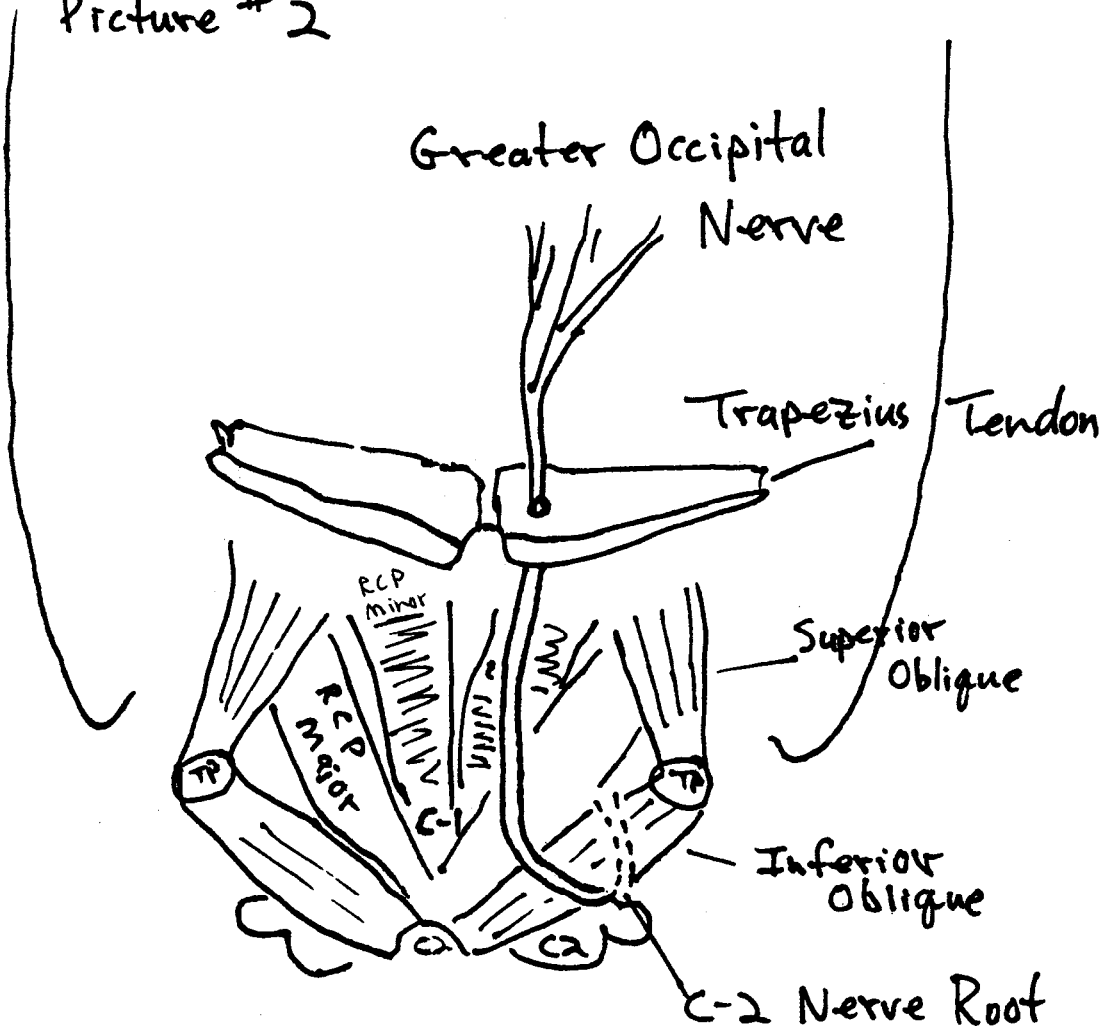
- 4) The **trigemincervical nucleus** is “defined by its afferent fibers.” **[Key]**
- 5) The **trigemincervical nucleus** receives afferents from the following sources:
- A)) Trigeminal Nerve (Cranial Nerve V)
 - B)) Upper three cervical nerves
 - C)) Cranial Nerve VII (Facial Nerve)
 - D)) Cranial Nerve IX (Glossopharyngeal Nerve)
 - E)) Cranial Nerve X (Vagus Nerve)
- All of these sources of afferents terminate on common second-order neurons in the **trigemincervical nucleus**.
- 6) Trigeminal nerve afferents will descend to the level of C3 and perhaps as low as C4.
- 7) The **trigemincervical nucleus** is the sole nociceptive nucleus of the head, throat and upper neck. “All nociceptive afferents from the trigeminal, facial, glossopharyngeal and vagus nerves and C1-C3 spinal nerves ramify in this single column of grey matter.”
- 8) Pain in the forehead can arise as a result of stimulation by cervical afferents of second-order neurons in the **trigemincervical nucleus** that happen also to receive forehead afferents.
- 9) Pain in the occiput (primarily innervated by C2) may arise from trigeminal nerve stimulation.
- 10) Because the ophthalmic branch of the trigeminal nerve extends the farthest into the **trigemincervical nucleus**, cervical afferent stimulation is most likely to refer pain to the frontal-orbital region of the head.
- 11) The stimulation of any neurons that activate the **trigemincervical nucleus** can cause headache, which included cranial nerves V, VII, IX, X, and C1-C3. “Any structure innervated by these nerves is capable of causing headache.” **[Key Point]**
- 12) Structures innervated by C1-C3:
- Dura mater of the posterior cranial fossa
 - Inferior surface of the tentorium cerebelli
 - Anterior and posterior upper cervical and cervical-occiput muscles
 - OCCIPUT-C1, C1-C2, and C2-C3 joints
 - C2-C3 intervertebral disc
 - Skin of the occiput
 - Vertebral arteries
 - Carotid arteries
 - Alar ligaments
 - Transverse ligaments
 - Trapezius muscle

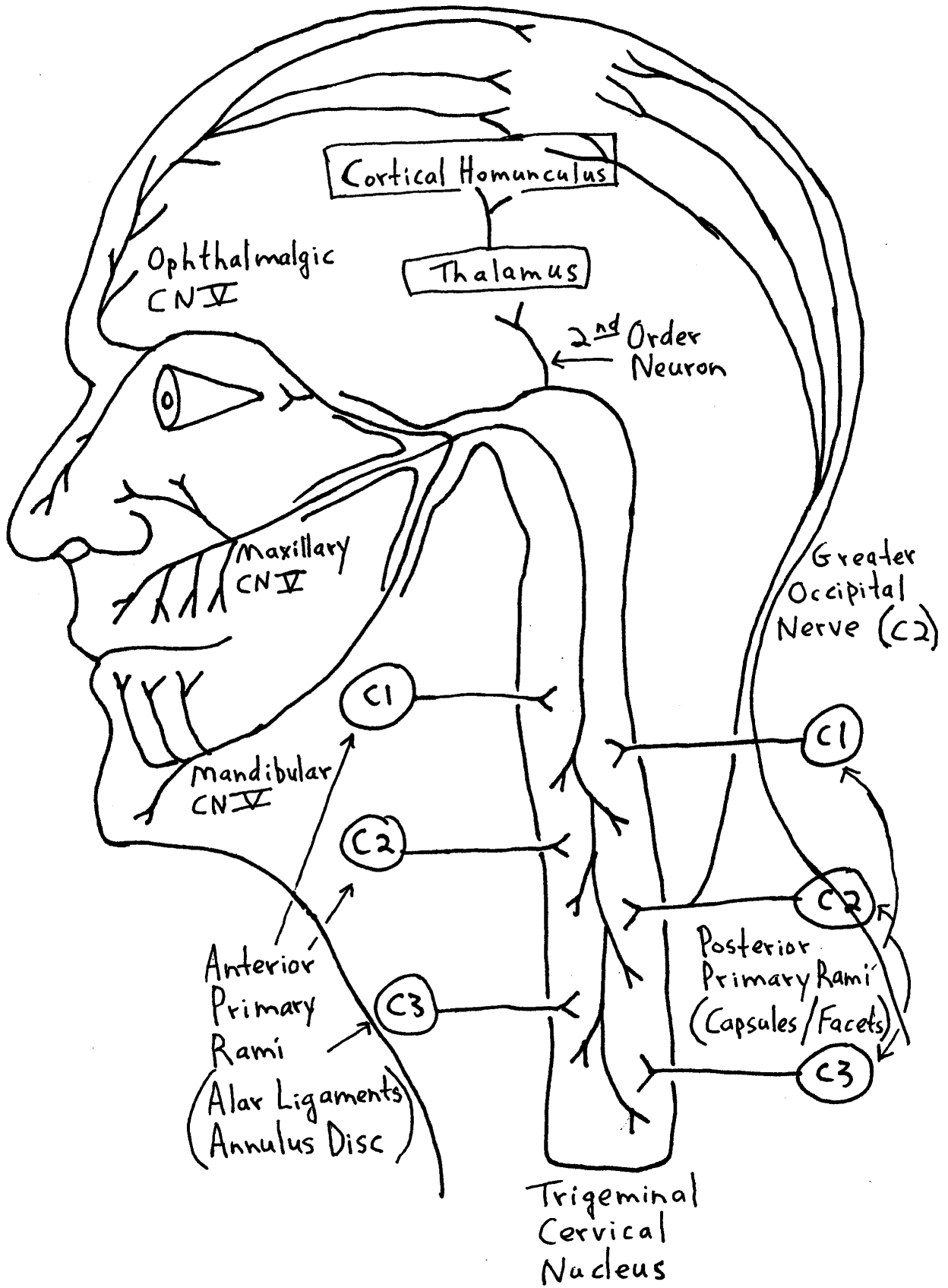
Sternocleidomastoid muscle

- 13) "The C1 and C2 spinal nerves are distinctive in that they do not emerge through intervertebral foramina."
- 14) C1 spinal nerve does not supply the skin, but does supply sensory innervation to the suboccipital muscles.
- 15) The C2 spinal nerve crosses the posterior aspect of the C1-C2 facet joint and innervates it.
- 16) The anterior primary rami of C1-C2-C3-C4 join and form the cervical plexus to innervate the prevertebral muscles: longus capitis, longus cervicis, rectus capitis anterior, rectus capitis lateralis, sternocleidomastoid and trapezius.
- 17) The anterior primary rami of C1-C2-C3 form the recurrent meningeal branches of the sinuvertebral nerves. These nerves innervate the anterior surface of the upper cervical dura mater, and then pass through the foramen magnum to innervate the dura matter between the pituitary gland to the anterior occiput (the clivus). They also innervate the medial portion of the C1-C2 joint capsule, the transverse and alar ligaments.
- 18) In the posterior cranial fossa, C1-C3 sinuvertebral nerves add components to cranial nerve X (vagus) and XII (hypoglossal). **[WOW!]**
- 19) The anterior primary rami from C1-C3 join the vertebral nerve, the plexus of nerves that travels with the vertebral artery, and supplies sensory branches to the fourth part of the vertebral artery.
- 20) The posterior primary rami of C1 innervate the 4 suboccipital muscles: inferior oblique, superior oblique, rectus capitis posterior major, rectus capitis posterior minor.
- 21) The motor component of the C2 posterior primary rami innervates the longissimus capitis and splenius.
- 22) The sensory component of the C2 posterior primary rami becomes the greater occipital nerve. It winds under the inferior oblique muscle, ascends and pierces the shared aponeurosis of the trapezius and sternocleidomastoid muscle to supply the posterior scalp.
- 23) The motor components of the C3 posterior primary rami also innervate the longissimus capitis and splenius muscles as well as the C2-C3 multifidus muscle.
- 24) The sensory component of the C3 posterior primary rami runs across the posterior aspect of the C2-C3 facet joint (which it innervates) and ascends as the third occipital nerve to supply the suboccipital region.

- 25) Nociception pain can be initiated by the accumulation of inflammatory chemicals.
- 26) Nociception pain can be caused by mechanical stimulation following a "distortion of a network of collagen" such as ligament or dura mater. **[Important: this supports the mechanics of the subluxation]**
- 27) Central pain involves no tissue damage but results from dysfunction of the descending pain inhibitory pathways. **[Important: the journal Pain in November 1996 suggests that spinal adjusting relieves pain because it activates the descending pain inhibitory system.]**
- 28) Stretch on the dura mater can initiate mechanical pain. **[Important: there exists a connective tissue bridge between C1-C2 that attaches to the inferior oblique muscle and attaches to the dura mater. Biomechanical problems in this region can stretch the dura mater, initiating mechanical pain.]**
- 29) The posterior cranial fossa and its contents are innervated by cervical nerves.
- 30) "Vertebral artery disease, such as an aneurysm becomes an important differential diagnosis of what otherwise might seem to be neck pain with referred pain to the head."
- 31) Arthritis of the upper cervical synovial joints (including C2-C3) can cause neck pain and headache.
- 32) Injury and damage to the alar ligaments can cause upper cervical pain and headache.
- 33) Posterior cervical muscle tears are not a cause of chronic headache.
- 34) C2 neuralgia is a neurogenic headache that can be caused by "scar tissue following trauma to the lateral atlanto-axial joint." **[Important]**
[Fibrosis of the C1-C2 facet joint affecting the adjacent C2 root]

Picture # 2





Greater Occipital Nerve
Posterior Rami C2

